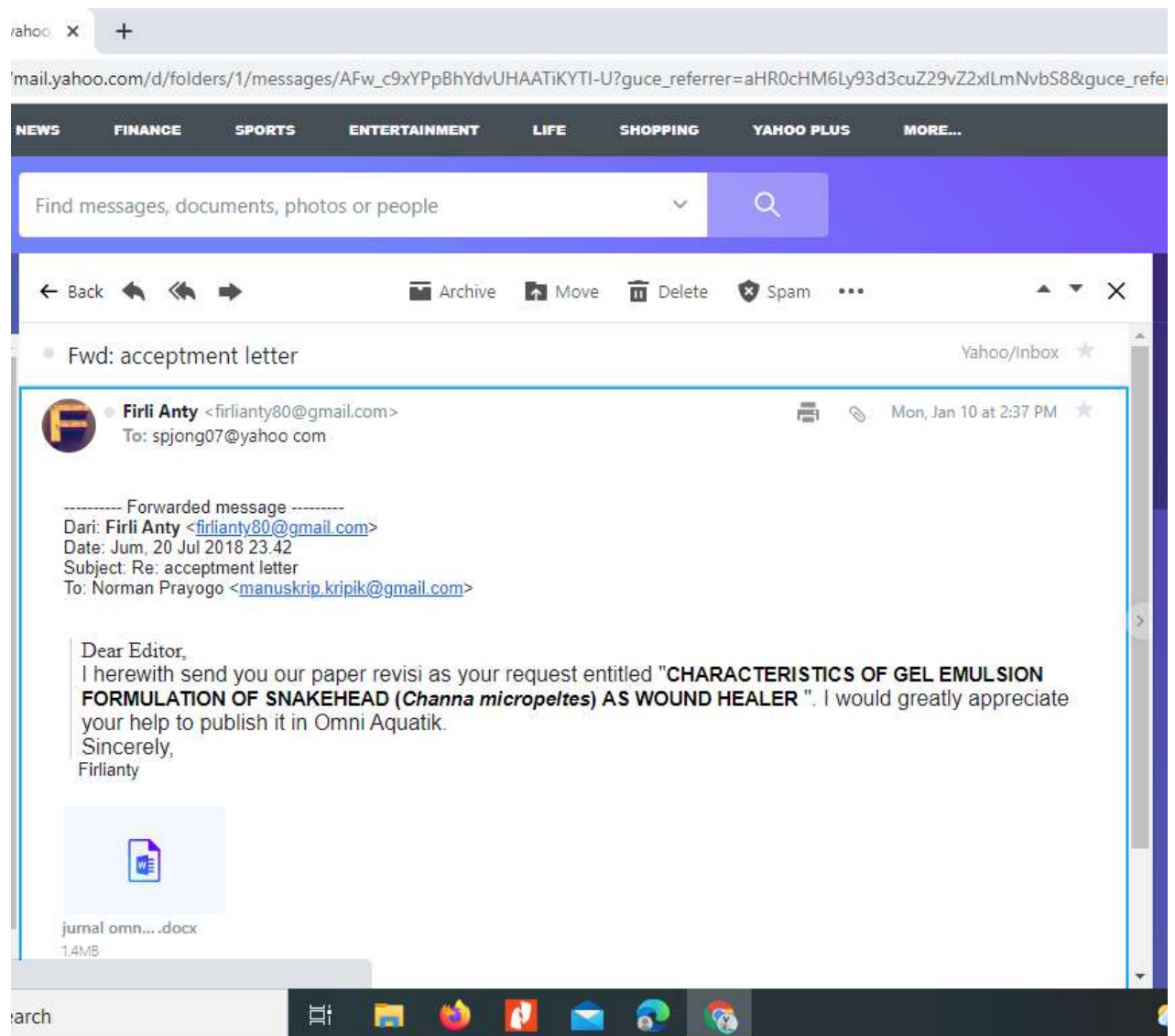

**Gambar 4. Hasil Revisi**

# CHARACTERISTICS OF GEL EMULSION FORMULATION OF SNAKEHEAD (*Channa micropeltes*) AS WOUND HEALER

Firlianty<sup>1</sup>, Choirul Anwar<sup>1</sup>, Elita<sup>1</sup>, Anang Najamuddin<sup>2</sup>, Silvester B. Pratasik<sup>3</sup>

<sup>1</sup>Study Program of Fisheries Product Technology, Dept. Fisheries, Faculty of Agriculture, Palangka Raya University

<sup>2</sup>Faculty of Agriculture, Palangka Raya University

<sup>3</sup>Faculty of Fisheries and Marine Science, Sam Ratulangi University Manado, Jl. Kampus Bahu, Manado-95115, Sulawesi Utara  
firlianty80@gmail.com

## ABSTRACT

This study is aimed to know the characteristics and the effectivity of gel emulsion of snakehead (*Channa micropeltes*) extract in accelerating wound healing process. It used experimental method with Complete Randomized Design. Four treatments with 3 replications were employed, i.e. 1%, 2%, and 4% gel emulsion of snakehead *Channa micropeltes* extract and a control treatment. Results showed that *C. micropeltes* extract formulated in gel emulsion had white colour, typical aroma of gel emulsion, soft texture with mean dispersion ability of 3 cm, and pH 6. *In vivo* test on male mice that gel emulsion of *C. micropeltes* extract was highly effective ( $P \leq 0.05$ ) to accelerate wound healing, in which the treatment of 1% gel emulsion gave the highest effect with 98.5% wound healing at day-14, followed with that of control treatment, 95% healing, then 2%, 90% healing and 4%, 90% healing, respectively. Snakehead (*Channa micropeltes*) extract formulated in gel emulsion can speed up the wound healing process.

**Keywords** : Gel emulsion, snakehead (*Channa micropeltes*), wound healing.

## 1. Introduction

Wounds are damages of body tissues often followed with loss of tissue substance that disturbs normal cellular process of the body, particularly skin (Sinambela *et al* 2013; Daisa *et al* 2017). Wound healing is a natural process of the body in regeneration of damaged skin tissue by supplying tissue perfusion, sufficient oxygen, and appropriate nutrition. One of the principles in wound healing is to provide enough nutrients since nutrient intake is specifically highly needed to increase the wound strength, to decrease dehydration, and to reduce the vulnerability to infection. Nutrient intake, such as carbohydrate, protein, fat, and micronutrients, is very important in increasing the body defense mechanisms to help wound healing process (Widjjaningsih & Wirjatmadi, 2013).

Toman snakeheads (*Channa micropeltes*) is one of the freshwater fishes that have body weight up to twice the other snakehead species and holds albumin protein. Albumin is protein type beneficial for new tissue formation of the body at the growth age and useful for nutrient supply in wound healing (Hairima *et al*

2014; Nicodemus *et al* 2014). Firlianty *et al* (2013) found that albumin content in *C. micropeltes* is high enough compared with that in other snakeheads, such as *C. striata*, *C. pleurophthalma*, and *C. lucius*. Beside that, *C. micropeltes* possesses high tape density of albumin protein and the most complete amino acids (Firlianty 2016). The use of albumin from *C. micropeltes* as wound healer has been practiced many times by consuming the fish as food or directly consuming the extract liquid. However, albumin of *C. Micropeltes* has fishy smell, and some people do not like it. Gel emulsion production is an alternative solution in wound healing drug development.

Gel emulsion, as one of good topical medicines in drug transport system, gel and emulsion releasing systems, in which the emulsion that could carry hydrophobic liquid extract of *C. micropeltes* is proportional to gel that possesses local effect to reduce pain at the inflammatory phase (Mutmainnah, 2015). Besides, gel emulsion is capable of efficiently bringing the active compound of *C. micropeltes* albumin to the skin evenly and maintaining it in the skin tissues and cells and gives pharmacological effects (Vikas, 2012).

This study was conducted to prove that gel emulsion characteristics of *C. micropeltes* extract and its effectivity on wound healing.

## 2. Material and Methods

This study was experimental using gel emulsion of snakehead (*Channa micropeltes*) extract to cure the white rat (*Mus musculus*) cut the dorsal part as long as 2 cm and about 2 mm deep. This therapy was done on 4 groups of the white rats at 0 (control), 1%, 2%, and 4% of gel emulsion of the extract.

### Emulsion Processing

Extract of *C. micropeltes* was dissolved in 0.5% span 80, 7.5% liquid paraffin up to forming liquid phase, and at the same time oil phase was accomplished by dissolving 1% tween 80 in distilled water up to forming oil phase. After oil phase and liquid phase had been gained, the oil phase was mixed into the liquid phase through heating up to reaching 70°C and stirred at 300 rpm for 15 min. up to emulsion formed.

### Gel Production

Gel was made by dissolving carbopol 934 and trietanolamine in distilled water and stirred at 400 rpm up to homogenous and gel basis formed.

### Gel Emulsion Production

Gel emulsion was made by adding with sediaan emulsi of *C. micropeltes* extract into the gel basis and stirred at 400 rpm for 20 min. up to gel emulsion of *C. micropeltes* extract formed

### Characteristic test and in vivo test

The characteristic examination of gel emulsion covered pH, dispersing ability, and organoleptic. *In vivo* test was done on male mice, *Mus musculus*, with weight range of 20 – 40 g that had been acclimated for 7 days and then treated with gel emulsion of *C. micropelte* twice a day for 14 days at a dose of 0.5 g. Wound healing development was observed at day-1, day-7, and day-14, respectively. Change in wound length was calculated using the following formula:

$$= \frac{\text{Change in wound in length (\%)} \times 100}{\frac{\text{Initial wound length} - \text{Wound length at day-n}}{\text{Initial wound length}}}$$

### Statistical Analysis

The experiment applied Complete Randomized Design with 4 treatments and 3 replications. ANOVA was used to see the effect on pH, dispersion, and change in wound length.

## 3. Result and Discussion

### Emulsion gel characteristics

The characteristics of gel emulsion and dispersion of *C. micropeltes* extract are presented in Figure 1, and the organoleptic in Table 1.

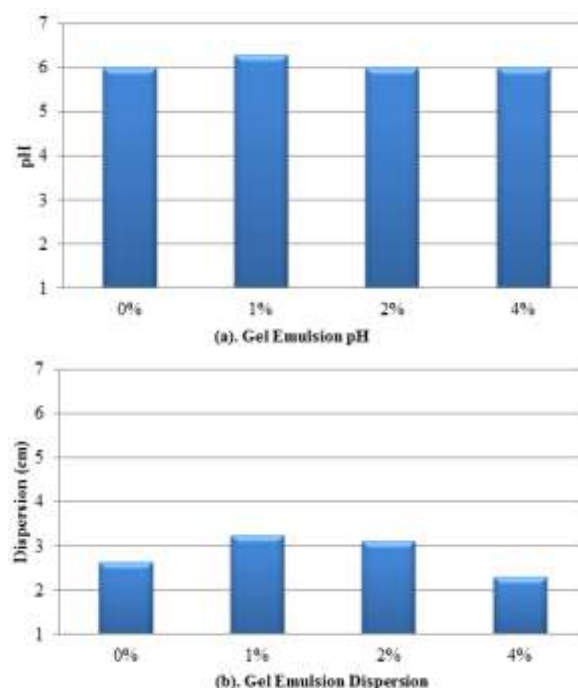


Figure 1. (a) Gel emulsion pH and, (b) Gel emulsion dispersion

Table 1. Organoleptic of gel emulsion of *C. micropeltes*

Formula	Color	Aroma	Texture
0%	white	Typical smell	Soft
1%	white	Typical smell	Soft
2%	white	Typical smell	Soft
4%	White	Typical smell	Soft

Measurements of pH are part of the gel emulsion examination (Figure 1a). ANOVA indicated that addition of *C. micropeltes* extract did not significantly affect the gel emulsion pH ( $P \geq 0.05$ ). Our findings are in the range suggested by Rowe et al., 2009, 4.5 – 6.4, so that the gel emulsion it is safe to use and does not cause skin irritation.

Dispersion ability is important in emulsion formulation to ease the application on the skin (Garg et al, 2002). ANOVA showed that addition of *C. micropeltes* extract significantly influenced the scatter of gel emulsion ( $P \leq 0.05$ )

in which treatment of 1% extract gave the highest dispersion with mean of 3.25 cm. Addition of 1%, 2%, and 4% of *C. micropeltes* extract to the gel emulsion could be well dispersed in the gel emulsion. *C. micropeltes* extract also contains albumin with flexible structure (due to change in disulfide) and the shape easily changes with environmental condition variations (Fitriayi & Deviarni, 2013).

For organoleptic test (Table 1), the addition of *C. micropeltes* extract to the gel emulsion did not give difference in organoleptic features, such as color, odor, and texture. The emulsion had white color, typical odor, soft texture, and no clumps of small particles

#### *In vivo test*

Percent wound healing development mice (*Mus musculus*), is presented in Figure 2

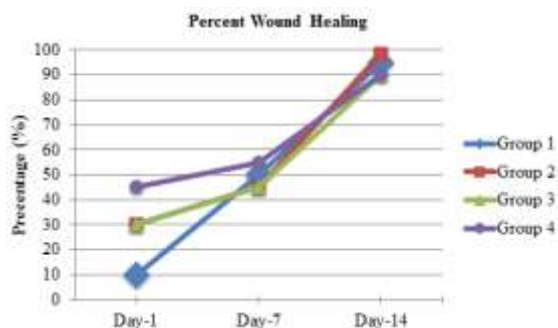


Figure 2. Percent wound healing

ANOVA showed significant difference among experimental groups ( $P \leq 0.05$ ), in which treatment of 1% extract gave the highest healing effect with mean 98.5% of healing at day-14. Each experimental group, in general, reflects wound healing as given in Figure 2.

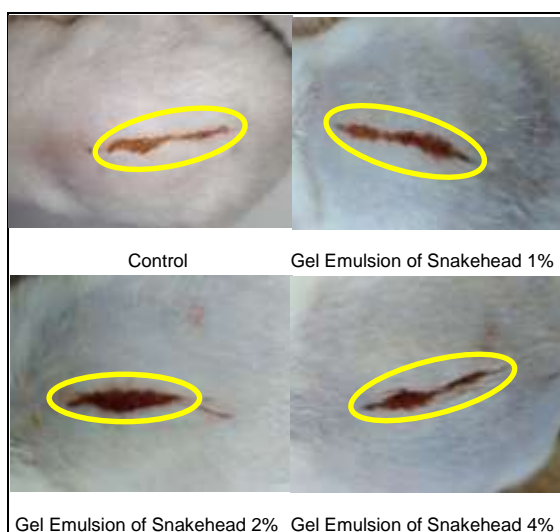


Figure 3. Wound conditions of negative control and gel emulsion of *C. micropeltes* at day-1

Wound healing process at day-1 naturally occurs as an early stage of wound healing called inflammatory phase. This phase starts from wound constriction due to skin inflammation caused by foreign materials from outside the body that enter through the open wounds, trigger a disturbance of hydrostatic pressure and cause different concentrations inside and outside the cell through the osmotic path (Alauddin, 2015). Figure 3 demonstrates natural wound healing. These conditions require albumin that can maintain the osmotic pressure inside and outside the cell, so that the healing process of the wound can continue.

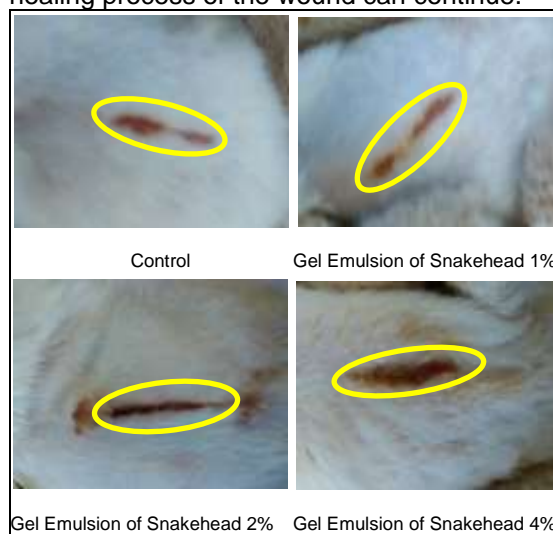
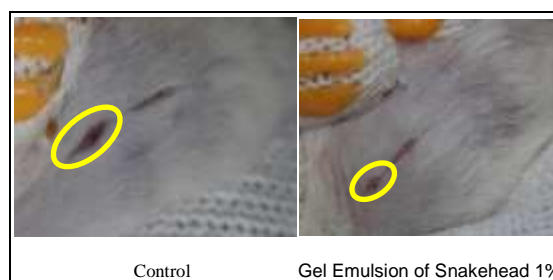


Figure 4. Wound Conditions of Negative Control and Gel Emulsion of Snakehead at day-7

At day-7, albumin absorption of gel emulsion of *C. micropeltes* extract on the wound occurred called proliferation phase. In this phase, albumin plays important role in closing the wound area. Figure 4 shows the wound healing in proliferation phase. Irwanda et al. (2014) added that during proliferation, albumin plays important role to influence the level and quality of wound healing, collagen formation, and collagen strength. Furthermore, amino acids and fatty acids, play important roles in the synthesis of collagen fibers during the wound healing process (Mustafa et al 2012., Wahab et al 2012., Tamales et al 2016).








Figure 5. Wound conditions of negative control and gel emulsion of *C. micropeltes* at day-14

At day-14, collagen reorganization occurred to form cell tissues and increased the collagen strength of the skin called maturation phase. Figure 5 demonstrates wound covering process. In this phase, albumin in the gel emulsion has important role in collagen formation. Wahab et al (2015) said that these two compounds were believed to be involved in the promotion of wound healing by the initiation of a series of mechanisms involving the remodelling of collagen, and reepithelialization of the wound.

#### 4. Conclusion

Addition of snakehead's *C. micropelte* extract formulated into gel emulsion had white color, typical smell of gel emulsion, soft texture with mean dispersion of 3 cm, pH = 6. *In vivo* test on male mice (*Mus musculus*), Gel emulsion of snakehead (*C. micropeltes*) can speed up the wound healing process.

#### References

- Alauddin, Ariq. 2015. The effect of snakehead (*Channa striata*) extract orally administered on cut wound of male wistar rat. Jurnal Mahasiswa Farmasi Fakultas Kedokteran UNTAN 3 (1): 1-12. [in Indonesian]
- Daisa, Fransisca., Andrie, Mohamad., & Taurina, Wintari. 2017. The Effectiveness Test of Oil Phase Ointment Containing Snakehead Fish (*Channa striata*) Extract on Open Stage II Acute Wounded Wistar Strain Male Rats. Traditional Medicine Journal 22 (7): 97-102.
- Firlianty., Suprayitno, Eddy., Nursyam, Happy., Hardoko., & Mustafa, Annasari. 2013. Chemical Composition and Amino Acid Profile of Channidae Collected From Central Kalimantan, Indonesia. International Journal of Science and Technology (IJSTE) 2 (4): 25-29.
- Fitriyani, Evi., & Deviarni, M.I. 2013. The use of snakehead (*Channa Striata*) extract albumin as basic material of wound healing cream. Jurnal Vokasi 9 (3): 166-174. [in Indonesian]
- Garg, Alka., Anggarwal, Deepika., & Singla, Anil K. 2002. Spreading of Semisolid Formulation. www.Pharmtech.com: 88-90.
- Hairima., Andrie, Mohammad., & Fahrurroji, Andhi. 2014. Activity test of liquid phase wound drug of snakehead (*Channa micropeltes*) extract on white wistar rat. Jurnal Mahasiswa Farmasi Fakultas Kedokteran dan Ilmu Kesehatan UNTAN 1 (1): 1-14. [in Indonesian]
- Irwanda, Welly F., Andrie, Mohammad., & Luliana, Sri. 2015. Test on the healing effect of liquid-phase toman snakehead (*Channa micropeltes*) extract on the cut wound of white wistar rat. Jurnal Mahasiswa Farmasi Fakultas Kedokteran dan Ilmu Kesehatan UNTAN 3 (1): 1-14. [in Indonesian]
- Laverius, Manda F. 2011. Tween 80 and Span 80 optimization as emulsifying agent and Carbopol as gelling agent in emulgel photoprotector preparation of green tea (*Camellia sinensis* L.) extract: Aplikasi Desain Faktorial. Fakultas Sanata Dharma. Yogyakarta: 1-71. [in Indonesian]
- Mustafa, Annasari., Widodo, M. A., & Kristianto, Yohanes. 2012. Albumin and Zinc Content of Snakehead Fish (*Channa striata*) Extract and Its Role in Health. IEEE International Journal of Science and Technology (IJSTE) 1 (2): 1-8.
- Mutmainnah. 2015. Formulation and characteristic test of emulger of snakehead (*Channa striatus*) extract. Universitas Islam Negeri Alauddin. Makassar: 1-64. [in Indonesian]
- Nicodemus., Andrie, Mohammad., & Luliana, Sri. 2014. Test on healing effect of oral administration of snakehead (*Channa micropeltes*) extract on cut wound healing of male wistar rat. Jurnal Mahasiswa Farmasi Fakultas Kedokteran dan Ilmu Kesehatan UNTAN 1 (1): 1-14. [in Indonesian]
- Rowe, Raymond C., Sheskey, Paul J., & Quinn, Marian E. 2009. Handbook of Pharmaceutical Exipients : Sixth Edition. Pharmaceutical Press and American Pharmacist Association : USA & UK. 110.
- Sinambela, Herry Yovieta., Pratiwi, Liza., & Sari, Rafika. 2013. Formulation optimization of cream preparation of snakehead (*Channa striata* Bloch) oil as cut wound drug using Simplex Lattice Design method. Lembaga Penelitian

- Universitas Tanjungpura:10-1. [in Indonesian]
- Tamales, Devintha AM., Dewi, Nurdiana, & Rosida, Lena. 2016. Extract of haruan (*channa striata*) extract increasing reepithelialization count in wound healing process on wistar rat's buccal mucosa. Journal of Dentomaxillofacial Science (J Dentomaxillofac Sci ) 1 (1): 12-15.
- Vikas, Singla. 2012. Emulgel: A New Platform For Topical Drug Delivery: International Journal of Pharma and Bio Sciences:h. 485-498.
- Wahab, Siti Z., Kadir, Azidah., Hussain, Nik., Omar, Julia., Yunus, Rohaizan., Baie, Saringat., Noor, Norhayati., Hasan, Intan., Mahmood, Wan., Razak, Aranee., & Yusoff, Wan. 2015. The Effect of Channa striatus (Haruan) Extract on Pain and Wound Healing of Post-Lower Segment Caesarean Section Women. Hindawi Publishing Corporation Evidence-Based Complementary and Alternative Medicine. <http://www.hindawi.com>: 1-6.
- Widjjaningsih, Elok., & Wirjatmadi, Bambang. 2013. Hubungan Tingkat Konsumen Gizi dengan Proses Penyembuhan Luka Pascaoperasi Section Cesarea. Jurnal Media Gizi Indonesia 9 (1): 1-5. [in Indonesian]