

Compose

- Inbox 4,682
- Starred
- Snoozed
- Important
- Sent
- Drafts
- Categories
- Social 886
- Updates 4,406
- Forums
- Promotions 5,314
- More

- Labels +
- Notes
 - More

10 of 10

Thank your for your submission

Teikyo Medical Journal <no-reply@teikyomedicaljournal.com> to me
Mon, Dec 13, 2021, 11:48 PM

Teikyo Medical Journal

Dear Dr Ferra Olivia,

Thank you for your submission into "Teikyo Medical Journal". Please use this paper ID: "TMJ-13-12-2021-10880" for your further inquiry for the publication. The paper will now go through peer review process and you will be notified within 7 working days about your submitted paper.

Thank you,

Admin Board

Teikyo Medical Journal

For Any Queries, Please mail to support@teikyomedicaljournal.com and related documents mail to admin@teikyomedicaljournal.com

Compose

- Inbox 4,402
- Starred
- Snoozed
- Important
- Sent
- Drafts
- Categories
- Social 805
- Updates 4,405
- Forums
- Promotions 5,114
- More
- Labels
- Notes
- More

Teikyo Medical Journal <no-reply@teikyomedicaljournal.com>
to me

Dec 16, 2021 8:26 AM

Teikyo Medical Journal

Dear Dr. Ferra Olivia,

Thank you for Submitting your manuscript into **Teikyo Medical Journal**. We are Pleased and honored to inform you that your paper **"ISOTRETINOIN and GLUTATHIONE COMBINATION vs ISOTRETINOIN ALONE ON SEVERE ACNE VULGARIS"** has been accepted by our Editorial board for the next issue of **Teikyo Medical Journal**.

The current condition of the paper is fully ok and need no further edit for the publications. The editor is really pleased to see this kind of paper and the research applications. In order to proceed for publication, kindly send the Application process charge of the publication within 7 days and submit the completed copyright Agreement paper into your Author Dashboard or through the mail, you can submit it as soon as your payment is done.

If you have any query, Please do not hesitate to mail us. Please fill your paper ID in to the subject of the mail for further inquiry. We eagerly await your response.

Thank you,

Admin Board

Teikyo Medical Journal

For Any Queries, Please mail to support@teikyomedicaljournal.com and related documents mail to admin@teikyomedicaljournal.com

Compose

- Inbox 4,402
- Starred
- Snoozed
- Important
- Sent
- Drafts
- Categories
- Social 805
- Updates 4,405
- Forums
- Promotions 5,114
- More
- Labels
- Notes
- More

Congratulations! Your paper has been Published.

Teikyo Medical Journal <no-reply@teikyomedicaljournal.com>
to me

Fri, Dec 31, 2021, 8:12 PM

Teikyo Medical Journal

Dear Dr. Ferra Olivia,

We are very pleased to inform you that your paper "ISOTRETINOIN and GLUTATHIONE COMBINATION vs ISOTRETINOIN ALONE ON SEVERE ACNE VULGARIS" has been successfully gone through for all procedure to the publication in "Teikyo Medical Journal".

Your paper has been published and now you can see it and refer it for your further research. We hope you to publish with your near future.

For preventing data breach from aimbot and third party we have secured your data. You will need an access key to see and download your paper. you can see your access key in your Author dashboard. please share this with your co-authors so that they can also download.

We hope you to publish with your near future.

Thank you,

Admin Board

Teikyo Medical Journal

For Any Queries, Please mail to support@teikyomedicaljournal.com and related documents mail to admin@teikyomedicaljournal.com

ISOTRETINOIN and GLUTATHIONE COMBINATION vs ISOTRETINOIN ALONE ON SEVERE ACNE VULGARIS

Ferra Olivia Mawu¹, Anis Irawan Anwar², Khairuddin Djawad³, Muh.Nasrum Massi⁴, Ilhamjaya Patellongi⁵, Pieter Levinus Suling⁶, Farida Tabri⁷, Siswanto Wahab⁸, Agussalim Bukhari⁹, Firdaus Hamid¹⁰

Department of Dermatology and Venereology, Faculty of Medicine, Sam Ratulangi University, Manado, Indonesia^{1,6}

Department of Dermatology and Venereology, Faculty of Medicine, Hasanuddin University, Makassar, Indonesia^{2,3,7,8}

Department of Microbiology, Faculty of Medicine, Hasanuddin University, Makassar, Indonesia^{4,10}

Department of Clinical Nutrition, Hasanuddin University, Makassar, Indonesia⁹

Department of Physiology, Hasanuddin University, Makassar, Indonesia⁵

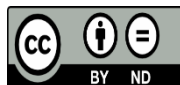


Keywords:

acne vulgaris, isotretinoin, glutathione.

ABSTRACT

Acne vulgaris (AV) is a chronic inflammation of pilosebaceous unit that is common in teenagers. According to its severity degree, AV can be categorized as mild, moderate, and severe. One of its alternative therapies on severe AV is isotretinoin. Oxidative stress affects the formation of acne vulgaris, therefore the antioxidant is considered as an additional therapy. Glutathione is of the antioxidants which has a protective effect on oxidative stress. Two male patients age of 20 years old suffered from severe AV for approximately a year. Both of the patients had several therapies but had not improved, by which one patient being treated with the combination of isotretinoin and glutathione and the other with isotretinoin alone for 4 weeks. Inflammation is one of the factors on the pathogenesis of AV. Isotretinoin as the first retinoid generation which functions as antiinflammation and immunomodulator, is one of the alternative therapies on mild AV. Oxidative stress is one of the causes of inflammation on AV. Glutathione is an antioxidant which functions as a protection to the oxidative stress. There is an improvement on severe-degree AV which treated with the combination of isotretinoin and glutathione as well as with isotretinoin alone.



This work is licensed under a Creative Commons Attribution Non-Commercial 4.0 International License.

1. INTRODUCTION

Acne vulgaris (AV) is a chronic inflammatory disease of pilosebaceous gland which can be recognized with the presence of polymorphic lesion such as comedone, papules, pustules, nodus, and cyst. The most common predilection is on the face area, but it can also appear on neck, shoulder, upper arm, chest, and upper back [1-3]. It is estimated that around 85% of AV happens on teenager and adolescent age of 12-25 years old, where male is more prevalent than woman. The process of acne formation happens temporarily on most of patients,

but the sequelae can happen during lifetime, with the formation of scar, especially on adolescent [1], [3], [4]. There are four pathogenesis that affect the formation of AV, which are: hyperproliferation of epidermal follicular, excessive sebum production, Cutibacterium acnes colonization, and inflammation and immune response [1], [2], [4], [5]. Nowadays, it has been acknowledged that the oxidative stress also related to AV pathogenesis, particularly on the inflammation process [6], [7]. The treatment of acne vulgaris is determined according to its severity degree which are mild, moderate, and severe. Treatment ranges from orally, topical, or combination [1- 5]. Additional therapy is also available, such as antioxidant which helps reduce inflammation caused by oxidative stress [8], [9]. The term severe acne was established using Lehmann criteria by lesion count to determine the acne severity [2], [8], [9]. According to acne treatment algorithm, isotretinoin oral is a treatment choice for severe AV [1], [2]. The regimens should meet all the pathogenesis pathways of AV and be used in combination to give maximum therapeutic response [1].

2. CASE PRESENTATION

We present two male patients, age 20 years old with severe AV. They have been suffering from the condition since in their teens. Both patients (A and B) complained from acneiform eruption some with painful small bumps. No history of AV in their families. No history of atopic condition in the patients as well as their families.

Patient A reported that he has had acne since 4 years ago and his acne became more severe on the past year and hardly vanished when the red papules showed up. Several facial papules contain pus and sometimes it also appeared on the back. Patient was a college student majoring on math and science, admitted that he sometimes felt stress due to loads of tasks, stay up late and facing the upcoming exams. He never used any skin care products, and his face skin tends to be oily and he wash his face twice daily. He also not on a specific diet. Patient had visited dermatovenereologist and treated with some oral antibiotics, ointment, and injection on its acne lesion. However, the patient experienced there were no significant clinical improvement.

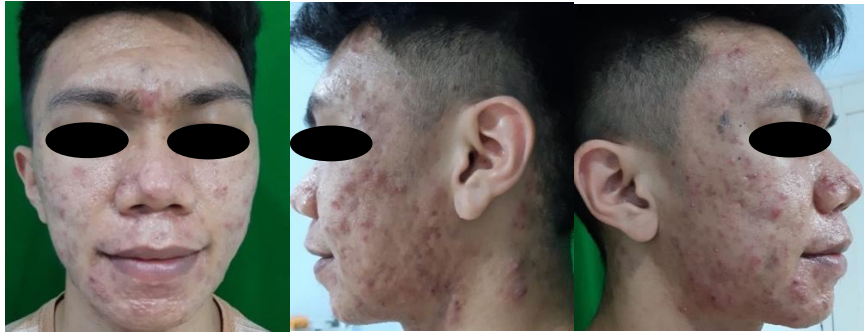Patient B

Patient complained of reddish bumps on his face, firstly appeared approximately 2 years ago with recurrent pattern. It became more severe on the past year and hardly vanished when the red papules showed up. Several papules contain pus. Patient was a student and preparing for his military academic test. He did outdoor morning exercise routinely for a minimum of one hour. He never used any skin care products, and his face skin tends to be oily and he wash his face twice daily. He is not avoiding any certain foods. Patient had visited dermatovenereologist and treated with some oral antibiotics and acne ointment.

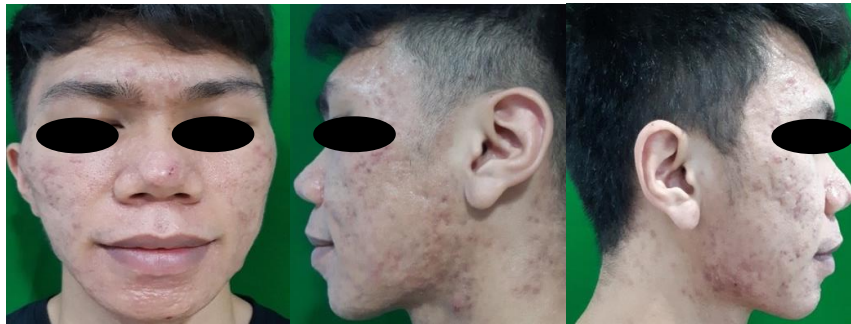On both patient, physical examination did not reveal any abnormalities. Laboratory examinations showed results from hematological and biochemistry within normal ranges.

Dermatological examination showed multiple comedones, erythematous papules, pustules, with total number of lesions >125. Diagnosis for both was severe acne vulgaris. Patient A was treated with 30 mg of isotretinoin administration per day plus 500 mg of oral glutathione per day. Patient B was treated with 30 mg of isotretinoin only. All medicines consumed for 4 weeks. Sunscreen with SPF 30 was given to them.

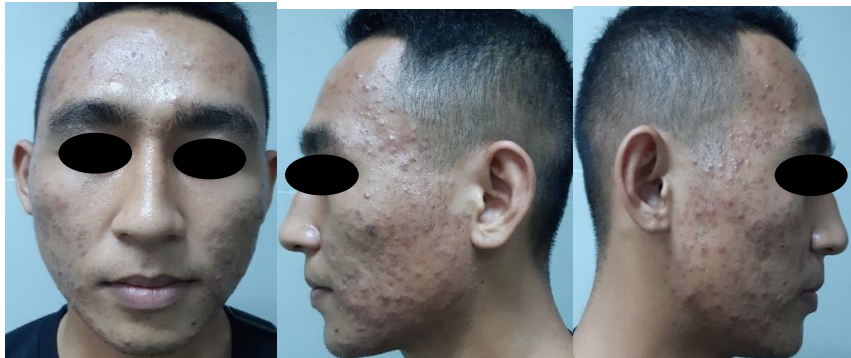Patient A. Baseline (Total number of lesions >125)



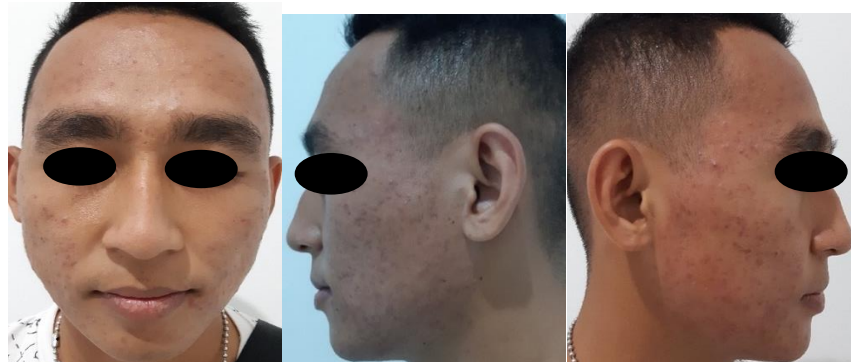Patient A. After 4 weeks of treatment (Total number of lesions ± 40)



Patient B. Baseline (Total number of lesions >125)



Patient B. After 4 weeks of treatment (Total number of lesions ± 50)



3. DISCUSSION

Acne vulgaris is pilosebaceous unit disease which commonly found in teenagers and adolescents particularly in male. Clinical appearance of pleiomorphic lesions could be non-inflammation lesions which is comedone (blackheads and whiteheads).; and the inflammatory lesions including papules, pustules, nodules, and also

scar. The most predilection sites are face, chest, and back. Both of the cases are males aged 20 years old with the chief complaint of multiple red papules which half-contained pus on face. It was appeared 4 years ago in patient A and 2 years ago in patient B. The red papules on both cases were recurrent and worsened since this past year where the newly papules became harder to treat and take longer time to improved. The acne severity degree based on the Lehmann (2002) are mild (comedone <20, pustules <15, cyst = 0, total lesions <30), moderate (comedone 20-100, pustules 15-50, cysts <5, total lesions 30-125), severe (comedones >100, pustules >50, cysts >5, total lesions >125) [2], [8]. In both cases, the patients have comedone, papule, and pustule type of lesion with total number of lesions > 125, therefore the patients categorized as severe degree of AV. The acne management determined based on its severity degree. In mild acne, the recommended treatments are topical retinoid or benzoil peroxide (BPO) or combination of BPO + topical antibiotic (AB); in moderate acne the recommendations are combination of BPO + topical AB or topical retinoid + BPO or BPO + topical retinoid + topical AB or oral AB+ retinoid + BPO or oral AB + retinoid + BPO + topical AB or alternative oral isotretinoin; in severe acne the available recommendation are oral AB + BPO + AB or retinoid + BPO + AB or intralesional corticosteroid or oral isotretinoin [1], [2], [5], [9]. Isotretinoin is an isomer of retinoic acid which is an inactive form of vitamin A and has been approved by the FDA as a therapy for severe acne and also recalcitrant acne. Isotretinoin acts to reduce sebum production by reducing proliferation of sebaceous basal differentiation, and sebaceous gland atrophy. It also gives effect as antiinflammation on the process of follicular hyperkeratinization and reduce the colony number of *P. acnes* [1], [4], [9- 11]. The recommended isotretinoin dose for moderate acne is 0.5 mg/kg/day for 30 days continued as 0.5 mg/kg/day for 10 days for each month until the total treatment for a minimum of 6 months [5], [9- 12]. In this case, both of the patients have a history of being treated with some methods, but has not been satisfactory enough, therefore the patients were given the alternative therapy of oral isotretinoin with doses of 30 mg/day for 4 weeks. There were improvements on both patients during 4 weeks observation of oral isotretinoin administration where the number of lesions reduced and the recovery time seemed shorter compared to the previous therapy. Nonetheless, the oral isotretinoin administration on both patients were still recommended to be continued until a minimum of 6 months.

Isotretinoin has several side effects, including dryness to desquamation skin effects, and mucosal effects which mostly happened on eyes, nose, and lips, and also extra cutaneous effects such as dizziness, fatigue, digestive problems, joint and muscle pain. Additionally, isotretinoin can also cause abnormalities in laboratory values, such as hyperlipidemia (cholesterol and triglyceride), high level of transaminase serum and creatinine. It is recommended to do a blood examination prior to treatment, after 6 weeks of therapy, and every 3 months of therapy [4], [10], [11]. During the administration of isotretinoin, both cases did not experience any side effects, nor from cutaneous and extracutaneous, and both of cases were being examined through laboratory, consisted of complete blood count, lipid profile, transaminase serum, and creatinine prior to isotretinoin administration, with a normal result. In several studies from the last couple of years, it was found the presence of oxidative stress which known to have a role in inflammation process on acne. Oxidative stress occurred because of the imbalance of *reactive oxygen species* (ROS) and antioxidant as the cellular defensive capacity [6], [7], [13]. Glutathione is a cellular antioxidant which has a protective function on oxidative stress, detoxification of toxin and carcinogenic materials, and helps to maintain body defense system [14], [15]. Glutathione is also known as skin-lightening agent both orally and topical. Glutathione inactivates tyrosinase and reduce dopaquinone production which altered the pigmentation process, and it also interacts with dopaquinone to become glutathionyl-dopa which produces *phaeomelanin* (*light-pigment*). In one study, glutathione 500 mg/day for 4 weeks gives a lighter skin result [16], [17]. In patient A, as the addition to oral isotretinoin administration, the patient was also given oral glutathione 500 mg per day for 4 weeks. The lesion improvement appeared after 1 week of oral isotretinoin and glutathione combination which was evaluated through the decrease of lesion numbers. The additional glutathione therapy was also helps to

reduce after-inflammatory hyperpigmentation. This is subjectively evaluated.

As it has been acknowledged in inflammatory lesions, the after-inflammatory hyperpigmentation appeared as the consequence of the disease sequelae which also become a burden for its sufferer. Therefore, the clinician mostly adds adjuvant therapy such as sunscreen use to prevent the appearance or worsening of that effect. The use of photoprotection, which is sunscreen, is recommended on acne patients whom on retinoid therapy and post acne hyperpigmentation. ³ The sunscreen was applied on both patients with SPF 30 every 4 hours daily, including indoor and outdoor activity.

4. CONCLUSION

It was reported a case of moderate-degree acne vulgaris which treated with isotretinoin plus glutathione versus isotretinoin on males aged 20 years old. After 4 weeks of treatment, a satisfactory result was reported on both patients. Clinical improvement of AV lesions were more than 50% lesions count reduced based on Lehmann criteria. Lessen number of lesions on patient A could be affected by additional treatment of glutathione. However, this need to be confirmed with more cases in the future.

5. REFERENCES

- [1] Goh C, Cheng C, Agak G, Zaenglein A.L, Graber E.M, Thiboutot D.M, Kim J. In: Kang S, Amagai M, Bruckner A.L, Enk A.H, Margolis D.J, McMichael A.J, Orringer J.S, editor. Fitzpatrick's Dermatology in General Medicine; 9th ed. New York: Mc Graw Hill Inc, 2019: 1391-412.
- [2] Indonesian Cosmetic Dermatology Study Group. Indonesian Acne Expert Meeting 2015. Treatment guidelines of Acne in Indonesia. 2nd ed. 2015: 11-15.
- [3] Oon HH, Wong SN, Aw DC, Cheong WK, Goh CL, Tan HH. Acne management guidelines by the dermatological society of Singapore. The Journal of clinical and aesthetic dermatology. 2019 Jul;12(7):34.
- [4] Fenton C, Kang C. Isotretinoin is key in treating acne vulgaris. Drugs & Therapy Perspectives. 2021 Mar 11:1-7.
- [5] Zaenglein A.L, Thiboutot D.M. Acne Vulgaris. In: Bologna JL, Schaffer JV, Cerroni L, editor. Dermatology; 4th ed. Netherlands: Elsevier, 2018: 588-602.
- [6] Kardeh S, Moein SA, Namazi MR, Kardeh B. Evidence for the Important Role of Oxidative Stress in the Pathogenesis of Acne. Galen Medical Journal. 2019 Apr 10; 8:129.
- [7] Sahib AS, Al-Anbari HH, Raghif AR. Oxidative stress in acne vulgaris: an important therapeutic target. Journal of Molecular Pathophysiology. 2013 Apr 1;2(1):27-31.
- [8] Ramli R, Malik AS, Hani AF, Jamil A. Acne analysis, grading and computational assessment methods: an overview. Skin research and technology. 2012 Feb;18(1):1-4.
- [9] Zaenglein AL, Pathy AL, Schlosser BJ, Alikhan A, Baldwin HE, Berson DS, Bowe WP, Graber EM, Harper JC, Kang S, Keri JE. Guidelines of care for the management of acne vulgaris. Journal of the American Academy of Dermatology. 2016 May 1;74(5):945-73.
- [10] Bettoli V, Guerra-Tapia A, Herane MI, Piquero-Martín J. Challenges and solutions in oral isotretinoin

in acne: reflections on 35 years of experience. *Clinical, cosmetic and investigational dermatology*. 2019; 12:943.

[11] Chien AL, Vahlquist A, Saurat JH, Voorhees JJ, Kang S. Retinoids. Dalam: Kang S, Amagai M, Bruckner A.L, Enk A.H, Margolis D.J, McMichael A.J, Orringer J.S, editor. *Fitzpatrick's Dermatology in General Medicine*; 9th ed. New York: Mc Graw Hill Inc, 2019:3395-404.

[12] Tan AU, Schlosser BJ, Paller AS. A review of diagnosis and treatment of acne in adult female patients. *International journal of women's dermatology*. 2018 Jun 1;4(2):56-71.

[13] Sahib AS, Al-Anbari HH, Salih M, Abdullah F. Effects of oral antioxidants on lesion counts associated with oxidative stress and inflammation in patients with papulopustular acne. *J Clin Exp Dermatol Res*. 2012;3(5):1-6.

[14] Richie JP, Nichenametla S, Neidig W, Calcagnotto A, Haley JS, Schell TD, Muscat JE. Randomized controlled trial of oral glutathione supplementation on body stores of glutathione. *European journal of nutrition*. 2015 Mar 1;54(2):251-63.

[15] Ikeno H, Tochio T, Tanaka H, Nakata S. Decrease in glutathione may be involved in pathogenesis of acne vulgaris. *Journal of cosmetic dermatology*. 2011 Sep;10(3):240-4.

[16] Dilokthornsakul W, Dhipayom T, Dilokthornsakul P. The clinical effect of glutathione on skin color and other related skin conditions: A systematic review. *Journal of cosmetic dermatology*. 2019 Jun;18(3):728-37.

[17] Weschawalit S, Thongthip S, Phutrakool P, Asawanonda P. Glutathione and its antiaging and antimelanogenic effects. *Clinical, cosmetic and investigational dermatology*. 2017; 10:147.